

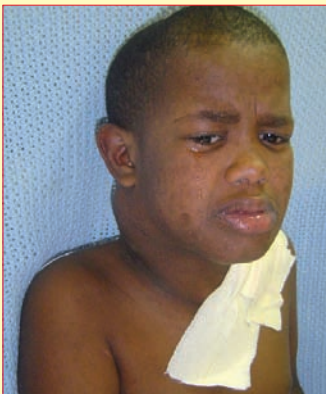# Anaesthesia and Job syndrome

**Bosenberg AT**

Department of Anaesthesia, University of Cape Town, South Africa

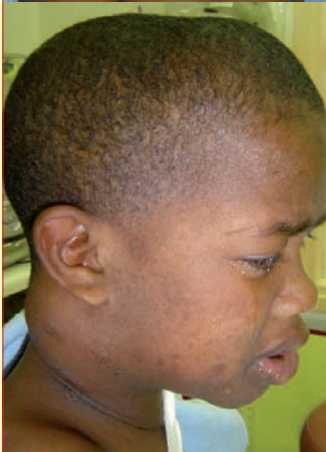**SAJAA 2008; 14(3): 11-14**

**Correspondence to:** Prof Adrian Bosenberg, e-mail: Adrian.Bosenberg@uct.ac.za



## Case report:

An 11-year-old male, weighing 29kg, presented for drainage and curettage of a recurrent abscess in the left supra-clavicular region. He gave a history of rhinorrhoea and chronic productive cough that his mother claimed was no worse than usual. He had eczema that was controlled with Betnovate and steroid cream and betadine shampoo since early childhood. He was receiving 12g immunoglobulin intravenously every month. He had had at least 18 general anaesthetics for drainage of multiple cold abscesses in the neck, groin, scrotum, elbow and face. *Staphylococcus aureus* and *candida albicans* were the usual organisms cultured. In addition he had a past history of a left staphylococcal empyema (21months); a right upper lobe bullectomy (4 years) and numerous chest drains for pneumatoceles. His effort tolerance was described as "surprisingly good" and he participated in normal sport activity at school. He regularly attended the dermatology clinic for eczema and persistent weeping lesions on the ears and face; and ENT clinics for chronic otitis media that had led to hearing deficit in both ears. He was on long term "rotational" antibiotics that included flucloxacillin and cotrimoxazole. Skin sensitivity tests were positive for milk, peanuts, soya, wheat, house dust mite and staph aureus; and negative for fish and eggs. He had a normal birth at term; he was breast-fed, was immunised and developmental milestones were normal. He had no significant family history although his mother was asthmatic.



On examination he was a happy child with coarse facial features and chronic eczema. He had a fruity cough, was afebrile and had a SpO<sub>2</sub> of 94% in room air. There was no clubbing or cyanosis. He had a left-sided fluctuant supraclavicular neck swelling and right supraclavicular lymphadenopathy. He had purulent otorrhoea in addition to gingivitis and poor dental hygiene. He was normotensive with a pulse rate of 85; heart sounds were normal and no clinical evidence of pulmonary hypertension. He had scattered rhonchi with coarse crepitations in his right chest. He had an Hb 9.8g/dl, white cell count 16000/dl with 9% eosinophilia and normal platelets. His chest X-ray had features of basal bronchiectasis. Previous X-rays showed multiple bilateral pneumatoceles. Previous special investigations showed IgE levels of >8000IU/ml. IgA, IgM and IgG were within normal limits.

Anaesthesia was uneventful. No premedication was required for this "frequent flyer" having his 23<sup>rd</sup> documented anaesthetic. He chose a sevoflurane induction via a T-piece circuit. Following induction he was converted to halothane in 35% oxygen and air via a Circle system. Nitrous oxide was avoided in view of the history of pneumatoceles

and pneumothoraces. Intraoperative SpO<sub>2</sub> ranged from 93-98% and end tidal CO<sub>2</sub> was initially 6.3Kpa but improved on halothane to 5.3Kpa. The skin edges of the chronic abscess cavity were infiltrated with 4ml 0.5% bupivacaine with adrenaline 1:200000. The abscess cavity was curetted and a biopsy taken. No additional analgesia was necessary and he was comfortable in recovery. Histology revealed an abundance of eosinophils in the wall of the abscess cavity typical of Job syndrome. *Staphylococcus aureus* was cultured.

## Introduction

Job's syndrome, an autosomal dominant disorder, was first described by Davis et al in 1966.<sup>1</sup> He called the disorder 'Job syndrome' after the biblical figure Job: '*So went Satan forth from the presence of the Lord, and smote Job with sore boils from the sole of his foot unto his crown*' (Job 2:7). Davis et al described two unrelated girls with lifelong histories of indolent Staphylococcal abscesses. Both had eczema soon after birth and had persistent weeping lesions on the ears and face. Both girls had red hair and were fair-skinned. The authors suggested a defect in local resistance to Staphylococcal infection.<sup>1</sup>

The syndrome was subsequently further defined and clarified by Buckley et al<sup>2</sup> who described similar patients who had markedly elevated IgE levels leading to the name "hyper-IgE syndrome" (HIES). As technology has advanced the girls described by Davis,<sup>1</sup> and other affected individuals, have had further more sophisticated investigations. In 1969, White et al<sup>3</sup> demonstrated normal leukocyte function while in 1974 Hill and Quie found a defect in neutrophil granulocyte chemotaxis in addition to the very high serum IgE levels in four girls, including the two described by Davis.<sup>4</sup> Most recently Renner et al demonstrated that one of the original patients, who now has two affected sons and a grandson, had a heterozygous mutation in the STAT3 gene.<sup>5</sup>

**Table I:** Incidence of typical clinical and laboratory findings in Job Syndrome (HIES)

Immune system	%	Skeletal	%	Lab findings	%
Eczema	100	Coarse facies	83	Elevated serum IgE	97
Skin abscesses	87	Wide nose	65	Eosinophilia	93
Pneumonia >3x or more	87	Primary teeth >3	72		
Pneumatocoles	77	Hyperextensibility	68		
Mucocutaneous candida	83	Path fractures	57		
		Scoliosis	63		

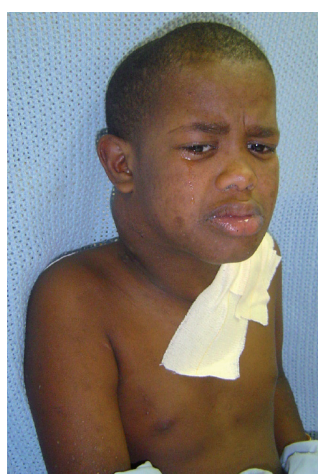In 2003, an autosomal recessive form with eosinophilia and elevated IgE levels was described in six consanguineous families from Turkey and Mexico.<sup>6</sup> These patients do not have any apparent abnormalities in their skeletal and dental systems but are prone to severe viral infections such as herpes simplex and refractory molluscum contagiosum. Although they have pneumonia with equal frequency, they do not develop pneumatocoles. Neurological involvement of unknown cause may be fatal.

#### Clinical manifestations

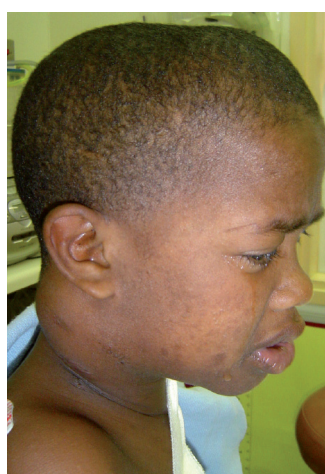Hyperimmunoglobulin E syndrome is a rare primary immunodeficiency characterised by the triad of markedly elevated serum levels of polyclonal immunoglobulin E (>2000IU/ml) with peripheral eosinophilia, recurrent staphylococcal infections of the skin and lungs, and chronic eczema. This triad is part of a multisystem disorder with abnormalities of the immune system; soft tissue, skeletal and dental systems varying in severity<sup>2,5,7-9</sup> (Table I) and identifiable in 77% of all patients and in 85% of those older than eight years.<sup>7</sup>

Although originally described in fair skinned females with red hair there is no racial or gender predilection. Patients have a distinctive phenotype whose coarse *facial features* include a prominent forehead with deep-set eyes, increased width of the nose, a full lower lip, and thickening of the nose and ears, and abnormal dentition.<sup>7,9,10,11</sup> (Figure 1) These facial features are universally present by 16 years of age.

**Figure 1a and 1b:** The typical facial features of Job syndrome are demonstrated i.e. coarse faces, prominent forehead, broad nasal bridge, and a bulbous nose. In addition bilateral lymphadenopathy, chronic eczema and surgical drainage of neck abscess is evident.



**Figure 1a**



**Figure 1b**

Given the constellation of clinical features and laboratory investigations, many of which are shared by other syndromes or diseases, a quantitative-phenotypic scoring system was developed by the US National Institutes of Health in 1999.<sup>7</sup> These criteria help to classify patients who are “likely to have the HIES genotype”.<sup>7</sup> (Table I)

*Skin manifestations* are severe if not treated. They present early with an atypical dermatitis in the neonatal period,<sup>6,12,13</sup> but may be mistaken for a nappy rash. The diagnosis is often missed unless there is a family history. Infants typically exhibit severe eczema complicated by mucocutaneous candidiasis involving the mouth and diaper areas in the first few weeks of life. The eczematous rash is pruritic, often lichenified, and affects the face, trunk, and extremities. Skin infections are frequent and start in infancy. Recurrent and multiple furuncles, cellulitis and deep-seated “cold” abscesses (pathognomic sign) are common features.<sup>8,14</sup>

A characteristic of HIES is the apparent lack of classic inflammatory responses even when the patients have severe skin abscesses or pneumonia caused by *Staphylococcal aureus* (most common), *Streptococcal pneumoniae* or *Haemophilus influenzae*. The patients are frequently unaware of how seriously ill they are because they feel well and are afebrile.<sup>8,14</sup>

Food and respiratory allergens can be identified using routine allergy testing; however, avoiding known allergens has minimal influence on the patient's dermatitis. These tests may be relevant for the anaesthesiologist bearing in mind the alleged cross sensitivity of propofol with egg or soya allergy. This child's skin sensitivity tests were positive for soya but not egg. He received propofol on a number of occasions without problem.

Certain distinguishing features may be used to differentiate the more common atopic dermatitis from HIES. In HIES, *Staphylococcus aureus* infections are deep seated, *non-Staph aureus* infections are frequent, respiratory allergy is rare, and onset is early, between 1-8 weeks. In atopic dermatitis, *Staphylococcus aureus* infections are superficial and involve the skin only, *non-Staph aureus* infections are rare, respiratory allergy is common, and onset occurs after 2 months of age.<sup>7</sup> Patients with HIE usually have coarse facial features, which is not a feature of individuals with atopic dermatitis.

*Pulmonary manifestations* may be extensive particularly when presentation is late or diagnosis delayed. The pulmonary infections are recurrent and severe. Complications include recurrent staphylococcal pneumonia with subsequent and usually persistent pneumatocoele formation,<sup>15</sup> lung abscess, bronchiectasis, bronchopleural fistula and empyema. Approximately 80% develop pneumatocoles<sup>16</sup> that are commonly associated with a chronic cough productive of purulent sputum.

The pneumatocoles may persist, expand, and become superinfected with bacteria and fungi (*vide infra*). Many will require chest tube drainage or surgical excision at some stage.

The presence of single or multiple pneumatoceles is the most striking radiographic feature.<sup>15</sup> (Figure 2)

**Figures 2a, 2b and 2c:** Series of chest X-rays taken prior to pneumonectomy at 4 years. The pneumatoceles are seen in both upper lobes, more prominent on the right. Massive pneumatocele which subsequently required a chest drain (2a)

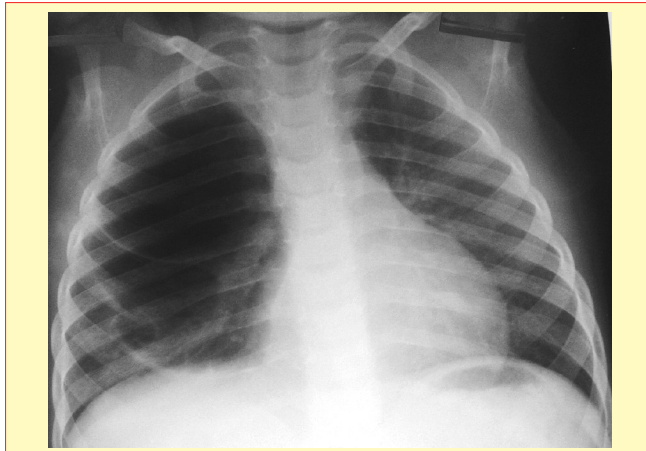


Figure 2a

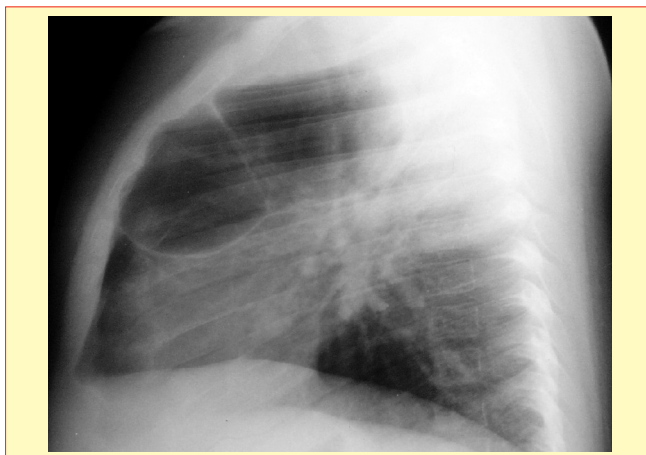


Figure 2b

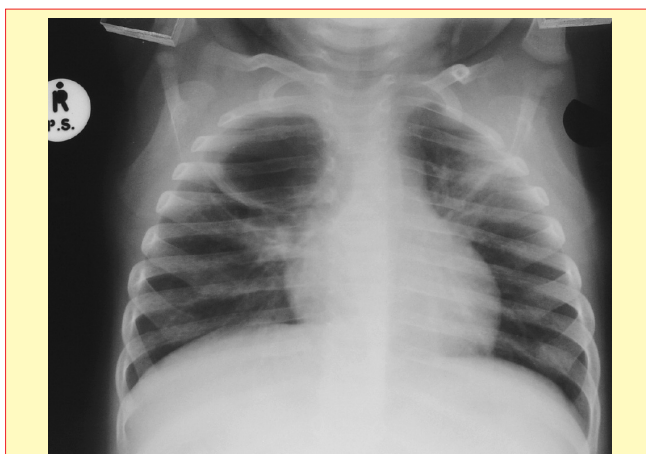

Figure 2c

**Figure 3:** Chest X-ray at 11 years immediately prior to abscess drainage. Bilateral basal bronchiectasis is evident.

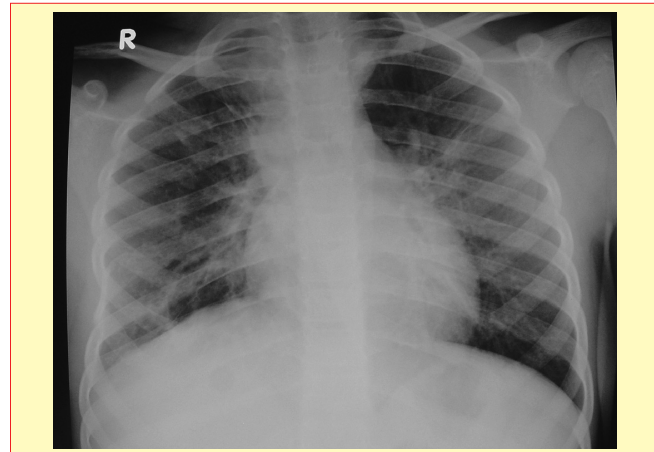


Figure 3

Deaths in the second and third decades of life due to severe pulmonary disease and infection of pneumatoceles with *Aspergillus* species *Pseudomonas aeruginosa*, *pneumocystis (carinii) jiroveci* or other organisms are likely but survival to the 6<sup>th</sup> decade has been reported.<sup>8,15,16</sup>

The *upper respiratory tract* may also be chronically infected causing sinusitis, discharging otitis media, otitis externa and mastoiditis. Rhinorrhoea may be difficult to control. Oral moniliasis is common. Recurrent chronic otitis media and sinusitis may persist into adulthood. Hearing deficit is common

*Skeletal anomalies* may require surgical intervention. Recurrent pathological fractures in osteopaenic bone are common findings (57%). Long bones, ribs, vertebrae, and pelvic bones are most commonly fractured. The mechanism for the osteopaenia is unclear. Other features include hyperextensible joints (68%), and scoliosis (76% of those older than 16 years).<sup>7</sup> Scoliosis may develop as a result of leg length discrepancy, a vertebral anomaly or following thoracotomy. Multiple rib fractures may also lead to asymmetry in the chest wall. Osteitis, usually staphylococcal, may be difficult to diagnose taking the lack of systemic signs into consideration.

*Dentition.* Primary teeth may be retained and prevent normal eruption of the permanent teeth. Failure or delay in shedding of the primary teeth due to lack of root resorption may be seen in up to 72% of cases.<sup>7</sup> It manifests as two rows of teeth and may require dental extraction.<sup>6</sup>

*Central nervous system* abnormalities have not been considered a feature of HIES until recently. Freeman et al demonstrated CNS abnormalities on brain MRI in 70% of patients scanned.<sup>17</sup> The focal hyperintensities and lacunar infarcts were more prevalent in adults than children.<sup>17</sup> The aetiology and clinical implications of these abnormalities is uncertain. Craniosynostosis has also been reported but is unusual.<sup>6,18</sup> Chronic inflammatory demyelinating polyneuropathy (CIDP) affecting motor function that improved after an intravenous infusion of immunoglobulin has been reported.<sup>19</sup>

#### Pathophysiology

The exact aetiology of HIES remains unknown. An inadequate inflammatory response as consequence of decreased neutrophil and leucocyte chemotaxis has been suggested,<sup>4</sup> but this is not a consistent finding. An imbalance between T-helper type 1 cell production of interferon-gamma (low) and a T-helper type 2 cell production of interleukin-4 (high) ratio has recently been suggested.<sup>8</sup>



Defects of cell-mediated immunity that include decreased or absent delayed-type hypersensitivity have been reported in some patients with HIES in addition to decreased lymphoproliferative responses to *S aureus*, *Candida* species, and tetanus antigens. Decreased numbers and functions of CD8<sup>+</sup> were also reported in some but these findings vary from patient to patient.<sup>8,14</sup>

### Genetics

Job syndrome or HIES could be caused by mutation of a single gene, mutations in different genes of a common pathway (genetic heterogeneity) or deletion of several genes in a short chromosomal region.<sup>8</sup> Several different mutations are most probably the cause of the genetic defect.<sup>8</sup>

Most cases are sporadic and, although there are differences in the phenotype, both autosomal dominant and autosomal recessive inheritance have been described.<sup>8</sup> The genetic basis of HIES was poorly understood and elusive until 2006 when a homozygous mutation in the tyrosine kinase 2 (tyk2) gene was discovered in a variant form of HIES.<sup>14</sup>

Subsequent studies have shown that HIES is inherited as an autosomal dominant disorder with variable expressivity.<sup>7</sup> The finding of heterozygous mutations in the DNA-binding domain of STAT3 gene in patients with HIES established that one form of the disorder maps to chromosome 17q21.<sup>5</sup> Others have suggested that proximal arm of 4q contains a disease locus for HIES based on an analysis of 19 families.<sup>7</sup>

The autosomal recessive form of HIES is characterised by severe recurrent viral infections, devastating neurological complications that are often fatal in childhood but lack the skeletal or dental involvement and do not develop cystic lung disease.<sup>8</sup>

### Therapy

There is as yet no cure for HIES. The goals of therapy are directed at prevention and management of infections by using sustained systemic antibiotics and antifungals along with topical therapy for eczema and drainage of abscesses.<sup>8</sup> Anti-staphylococcal antibiotic prophylaxis markedly reduces the incidence of skin abscesses and staphylococcal pneumonias.

Interferons, immunoglobulin supplementation, low dose cyclosporine A, plasmapheresis, and bone marrow transplantation may have benefit in selected patients<sup>8</sup> but are not generally indicated as the aetiologies of different forms of HIES are variable and complex. One therapeutic approach may benefit one but not necessarily all patients with HIES.<sup>8</sup>

### Anaesthetic considerations

Preoperative assessment should focus on respiratory function. This should include chest X-ray, CT scan, arterial blood gases and pulmonary function tests as indicated by the history and clinical examination. Pulmonary function tests are difficult to perform in young children. Age appropriate assessment of effort tolerance is equally predictive. Nitrous oxide should be avoided because of the high frequency of pneumatoceles. Selective bronchial intubation and isolation may need to be considered when a lung is severely infected but this should be balanced against the ventilation-perfusion mismatch and adequate oxygenation. Prophylactic antibiotics should be considered.

Considering the immunodeficiency, strict asepsis is needed for cutaneous puncture whether for venous access or regional anaesthesia. Regional anaesthesia is not contraindicated and may be a useful option in the presence of severe pulmonary pathology particularly when there is a significant risk of ventilator-induced pneumothorax (e.g. broncho-pleural fistula, rupture of a pneumatocele).<sup>20</sup>

The benefit of regional anaesthesia should be considered against the risk of abscess formation in an immuno-compromised patient. Epidural placement through chronically infected skin carries an

increased risk of infection. Abscesses tend to be indolent and do not present with the usual erythema, pain and inflammation. The familiar signs of epidural abscess formation may thus be masked. Neuraxial blockade has however been used successfully but it is difficult to draw conclusions from only two published cases.<sup>20,21</sup> As a rule of thumb placing the needle through or near "infected skin" should be avoided.

Repeat anaesthetics in children do not pose the same risks as in adults. "Halothane hepatitis" is not considered a problem in pre-pubertal children. Hepatitis has not been described in children following repeat anaesthetics with other inhalation agents. Of greater concern is the psychological impact of multiple anaesthetics. Time spent explaining the options and the procedure for these "frequent fliers" is vital. Fear of anaesthesia can be reduced and children will develop preferences if allowed to do so.

SAJAA

### References

1. Davis SD Schaller J Wedgwood RJ. Job's syndrome: recurrent 'cold,' staphylococcal abscesses. *Lancet* 1966; I: 1013-1015.
2. Buckley RH Wray BB Belmaker EZ. Extreme hyperimmunoglobulin E and undue susceptibility to infection. *Pediatrics* 1972; 49: 59-70.
3. White LR Iannetta A. Kaplan EL et al. Leucocytes in Job's syndrome. *Lancet* 1969; 1: 630.
4. Hill HR Quie PG. Raised serum-IgE levels and defective neutrophil chemotaxis in three children with eczema and recurrent bacterial infections. *Lancet* 1974; 1: 183-187.
5. Renner ED Torgerson TR Rylaarsdam S et al. STAT3 mutation in the original patient with Job's syndrome. *New Eng. J. Med* 2007; 357: 1667-1668.
6. Erlewyn-Lajeunesse MDS. Hyperimmunoglobulin E syndrome with recurrent infection: a review of current opinion and treatment. *Pediatr Allergy Immunol* 2000; 11: 133-141.
7. Grimbacher B Holland SM Gallin JI et al Hyper-IgE syndrome with recurrent infections—an autosomal dominant multisystem disorder. *New Eng J Med*. 1999; 340: 692-702.
8. Grimbacher B Holland SM Puck JM. Hyper-IgE syndromes. *Immunological reviews* 2005; 203: 244-250.
9. Donabedian H Gallin JI. The hyperimmunoglobulin E recurrent-infection (Job's) syndrome: a review of the NIH experience and the literature. *Medicine* 1983; 62: 195-208.
10. Borges WG Hensley T Carey JC, Petrak BA, Hill HR. The face of Job. *J Pediatr*. 1998; 133: 303-5.
11. Grimbacher B.; Schaffer, A. A.; Holland, S. M et al Genetic linkage of hyper-IgE syndrome to chromosome 4. *Am. J. Hum. Genet.* 65: 735-744, 1999.
12. Eberting CL Davis J Puck JM et al Dermatitis and the newborn rash of hyper-IgE syndrome *Arch Dermatol* 2004; 140: 1119-1125
13. Kamei R, Honig PJ. Neonatal Job's syndrome featuring a vesicular eruption. *Pediatr Dermatol.* 1988; 5(2): 75-82.
14. Minegushi Y Karasuyama H. Hyperimmunoglobulin E syndrome and tyrosine kinase 2 deficiency. *Curr Opin Allergy Clin Immunol* 2007; 7: 506-509.
15. Buckley RH. Pulmonary complications of primary immunodeficiencies. *Ped Resp Rev* 2004; 5 (suppl A): s225-233
16. Freeman AF, Kleiner DE, Nadiminti H, et al. Causes of death in hyper-IgE syndrome. *J Allergy Clin Immunol*.2007; 119 (5):1234-40.
17. Freeman AF Collura-Burke CJ Patronas NJ et al Brain abnormalities in patients with hyperimmunoglobulin E syndrome. *Pediatrics* 2007; 119: e1121-e1125.
18. Smithwick EM, Finelt M, Pahwa S Cranial synostosis in Job's syndrome. *Lancet.* 1978; 1(8068): 826.
19. Kimura A, Yoshino H, Yuasa T. Chronic inflammatory demyelinating polyneuropathy in a patient with hyperIgEaemia. *J Neurol Sci.* 2005; 231(1-2): 89-93.
20. Tapper JB, Giesecke AH. Spinal anaesthesia in a child with Job's syndrome, pneumatoceles and empyema. *Anaesthesia.* 1990; 45: 378-80.
21. Miller FL, Mann DL. Anesthetic management of a pregnant patient with the hyperimmunoglobulin E (Job's) syndrome. *Anesth Analg.* 1990; 70: 454-6.